Evaluation of Hair Growth Stimulation via PDO Polydioxanone Thread Application: An Observational Pilot Study

Alan J Bauman, MD, ABHRS, FISHRS
Bauman Medical Hair Transplant & Hair Loss Treatment Center | Boca Raton, FL | USA
33rd World Congress of the ISHRS | October 23-25, 2025 | Berlin

@DrAlanBauman

Introduction

- Androgenetic alopecia (AGA) impacts self-esteem and QoL.
- Current therapies (minoxidil, finasteride, LLLT, PRP, surgery) vary in effectiveness and compliance.
- PDO threads, FDA-cleared as surgical sutures since the 1980s, are biocompatible and biodegradable.
- Prior studies in humans and mice (Bharti 2017, Seo 2015). suggest PDO may stimulate hair growth through regenerative mechanisms.
- This pilot study investigates safety, feasibility, and hair regrowth outcomes.

Smooth PDO thread (29g)

Methods

Participants (n=4):

Males (NW5, NW6) and females (frontal/vertex thinning), ages 45–58 w/ AGA. No hair therapy or surgery.

Procedure:

Local anesthesia block + ProNox. Radial/parallel PDO thread insertion, 0.5–1.0cm spacing.

Thread sizes: 29g [25mm + 38mm]

Assessment tools & timing:

- Global photography
- Trichoscopy
- Hair Mass Index (HMI)
- Baseline, W6, W12, M6, M9, M12

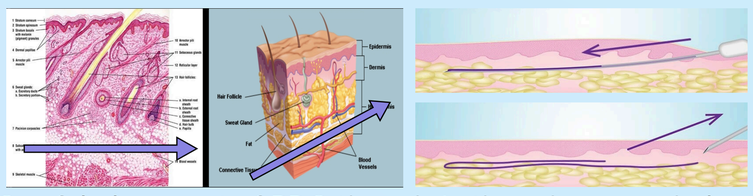

Careful placement of PDO threads in the subq space below the follicles and above the galea avoids follicular damage.

Intraoperative view of PDO thread placement

Results

- All patients showed increased density, thickness, and HMI.
- Example: One patient achieved +48% HMI at 6 months.
- Photography: Visible coverage improvement.
- Trichoscopy: Increased terminal hair counts, length, pigment, and caliber.
- Animal models confirm PDO enhances anagen phase, proliferation, and vascularization.

Results (con't)

CASE #1: Female, Hairline/Temple Thinning

52♀ AGA % thinning x 10yrs
h/o knee surgery, no current hair txs.
63 PDO threads (29g)
Hairline/temples to Midscalp
Photos: BL, M6; HMI: BL, W6, W12
Midscalp responded faster than temples. Temple coverage improved.

CASE #2: Female, Vertex Thinning

51♀ AGA % thinning crown x 5yrs,
h/o menopause, no current hair txs.
38 PDO threads (29g), Vertex
Photos: BL, M6; HMI: BL, M3, M6;
48% ↑HMI at M6

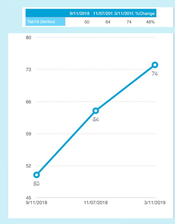

CASE #3: Male, NW5-6

45♉ NW5-6, no meds/no PMHx/no SxHx.
40 PDO Threads (29g), Front to Vertex
Photos: BL, M6; HMI: BL, M3, M6. Frontal coverage improved, part-width decreased.

CASE #4: Male, NW6

58♉ NW6, no hair meds, no surgery. h/o testosterone use, Ca+ channel blocker for HTN,
40 PDO Threads (29g), Front to Vertex
plus 7.0cc of PRP + perinatal ECM tissue
Photos & HMI: BL, M3, M6, M9
HMI increase lasted ~6-9mos

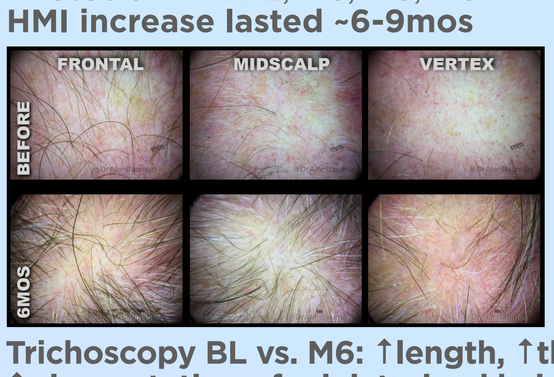

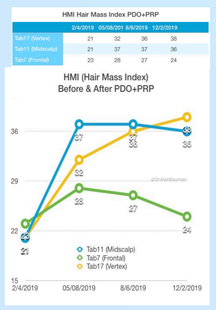

Trichoscopy BL vs. M6: ↑length, ↑thickness & ↑pigmentation of miniaturized hair in all areas.

Discussion

PDO threads may act through:

- Neo-collagenesis
- Improved blood supply
- Growth factor modulation (↑FGF-7, ↓FGF-5)

Safety:

Mild transient erythema, tenderness; rare extrusion.

Limitations:

Small observational cohort (n=4), no control group.

Larger controlled studies are needed to refine protocols, determine optimal timing for repeat treatments, and assess broader patient populations.

Take-Home Message

PDO threads stimulate clinically significant hair regrowth by enhancing the anagen phase, improving vascularization, and supporting follicular proliferation. They represent a safe, promising, minimally invasive, non-pharmaceutical option for managing AGA.

Conclusion

- PDO threads are a promising, minimally invasive, non-pharmacological, regenerative hair growth treatment.
- Can be used as standalone or adjunct to PRP, Exosomes, or FUE.
- Demonstrated strong safety profile and patient tolerance.

References

Middleton JC, Tipton AJ. *Qmed.com*, 1998.
Seo HS, et al. *J Pharmacopuncture*, 2015.
Bharti S, et al. JEADV, 2017.
Bauman AJ. PDO Hair Growth, SBS 2019.
Yoon JH, Kim SS, et al. *J Cosmet Dermatol*, 2019.
Bauman AJ. TED + PDO Hair Growth, IMCAS 2023.

SCAN ME
Scan for video, PDFs, references & additional resources

Thank you to the entire talented and passionate Bauman Medical team!